

# QUIZ

CORRECT ANSWER TO THE QUIZ. CHECK YOUR DIAGNOSIS

## MESENCHYMAL CHONDROSARCOMA OF THE ORBIT: TWO CASES AND A BRIEF REVIEW OF THE LITERATURE

ANNA SZUMERA-CIEĆKIEWICZ<sup>1</sup>, KONRAD PTASZYŃSKI<sup>1</sup>, PIOTR GRABOWSKI<sup>2</sup>, ROMUALD KRAJEWSKI<sup>2</sup>, MAŁGORZATA TACIKOWSKA<sup>3</sup>

<sup>1</sup>Department of Pathology, Maria Skłodowska-Curie Memorial Cancer Center and Institute of Oncology, Warsaw, Poland

<sup>2</sup>Department of Head and Neck Cancer, Maria Skłodowska-Curie Memorial Cancer Center and Institute of Oncology, Warsaw, Poland

<sup>3</sup>Department of Magnetic Resonance Imaging, Maria Skłodowska-Curie Memorial Cancer Center and Institute of Oncology, Warsaw, Poland

---

Mesenchymal chondrosarcoma (MChS) is a rare, high-grade malignant tumor which occurs both in the bone and soft tissue. The extraskkeletal location comprises one third of all MChS and in review of the up-to-date literature, about 30 cases of the orbital involvement were found. The authors present clinical, radiological and pathological findings of two cases of MChS of the orbit occurring in young adult females: primary extraskkeletal MChS of the orbit and skeletal MChS of the ethmoidmaxillary complex with secondary orbit involvement. The histopathological examination revealed a characteristic biphasic pattern composed of small round to spindle-shaped cells, mimicking Ewing sarcoma family of tumors, with areas of a haemangiopericytoma-like pattern and admixed cartilage foci. One of the patients had local recurrence 3 years after initial surgical removal. Subsequently, she underwent enucleation followed by chemotherapy. The other patient had a biopsy and debulking resection of the tumor and started chemotherapy. Ten months follow-up of this patient show no evidence of metastasis.

**Key words:** mesenchymal chondrosarcoma, chondrosarcoma, orbit, differential diagnosis.

---

### Introduction

---

Since mesenchymal chondrosarcoma (MChS) was first described over half a century ago, in 1959 by Lichtenstein and Bernstein [1], about 500 cases have been reported. The hallmark of this rare, highly malignant neoplasm is a bimorphic histological pattern composed of small undifferentiated round cells with islands of cartilage. The cellular areas frequently demonstrate perivascular arrangement resembling a haemangiopericytoma-like pattern.

The incidence of MChS varies from 1% to 13% of all bone chondrosarcomas. Clinical symptoms are nonspecific and include swelling, pain, palpable slow-

ly enlarging bone or soft tissue mass. It occurs most often in young adults, particularly in the second to fourth decade of life.

Cases of the skeletal location represent the majority accounting for 65-70%. Extraskkeletal lesions comprise approximately 30-35%. Single cases (7%) of osseous MChS were classified as multicentric [2]. The extraskkeletal MChS has a female predilection while the skeletal MChS affects men and women equally. In contrast to conventional chondrosarcomas, MChS of bone are found in the axial skeleton predominantly and the most frequently affected site is a craniofacial region (up to 30%) [2]. Majority of cases involves normal, unimpaired bone. The MChS arising as a secondary

lesion to the prior fibrous dysplasia has also been reported [3].

Extraskelletal MChS typically occurs in the lower extremities, usually as an intramuscular, thigh lesion [4]. Cases with the unique location in the brain and meninges, heart, kidney, thyroid gland and pancreas have also been reported [5, 6]. Approximately 30 cases of the orbital involvement were reported including two cases of congenital MChS [7-10].

We describe two cases of MChS of the orbit. Case 1 was classified as a primary extraskelletal MChS of the orbit. Case 2 was diagnosed as a skeletal MChS of the ethmoidmaxillary complex with secondary orbit involvement. Case 2 has been presented as a Quiz case.

## Case report

### Clinical presentation

Case 1: A 31-year-old female, without past medical history, complained of difficulties with nasal respiration and headaches during the right eye movement. Computed tomography showed a tumor of the right ethmoidmaxillary complex measuring 39 mm × 31 mm × 30 mm. Histopathology of the biopsy specimen revealed a small cell malignancy. Two months after initial diagnosis the patient was admitted to the Head and Neck Cancer Department of Maria Skłodowska-Curie Memorial Cancer Center for further evaluation and treatment. Physical examination revealed mild proptosis, restriction of the right eye mobility and anosmia. The chest X-ray and abdominal ultrasonography were normal with no evidence of metastatic disease.

Case 2: The case has been presented as a Quiz case. A 29-year-old female was admitted to the hospital with pain of her left eye and progressive proptosis for about 6 months. Ultrasound and computed tomography (CT) were performed and showed a tumor mass of the left orbit. Debulking of the tumor and subsequent pencil beam radiotherapy was performed. The patient developed tumor recurrence 3 years after the procedure with severe proptosis, movement restriction and blindness in the left eye. Magnetic resonance revealed tumor of the orbit encasing the left optic nerve and pushing forward the patient's eye. Chest X-rays showed no metastatic disease.

### Radiological imaging

Case 1: The magnetic resonance imaging demonstrated a well-delineated tumor of the right ethmoid bone 4.7 cm × 3.6 cm × 2 cm in size. The malignancy penetrated to the anterior part of cranium with focal meningeal involvement and extension to the medial side of the orbit. After intravenous contrast administration, the moderate heterogeneous enhancement of non-calcified component was noted (Fig. 1 A).

Case 2: The tumor was located in the upper part of the orbit with no evident involvement of the remaining orbital wall. In the magnetic resonance, a polycyclic, multinodular, well-delineated tumor invading the upper, medial and posterior part of the left orbit, 4.5 cm in diameter was found. The malignancy was attached to the eyeball and the optical nerve. The frontal bone and orbital roof defects were identified. The tumor demonstrated increased homogenous enhancement after intravenous contrast administration with focal areas of calcifications seen in T1 and T2-weighted images (Fig. 1 B).

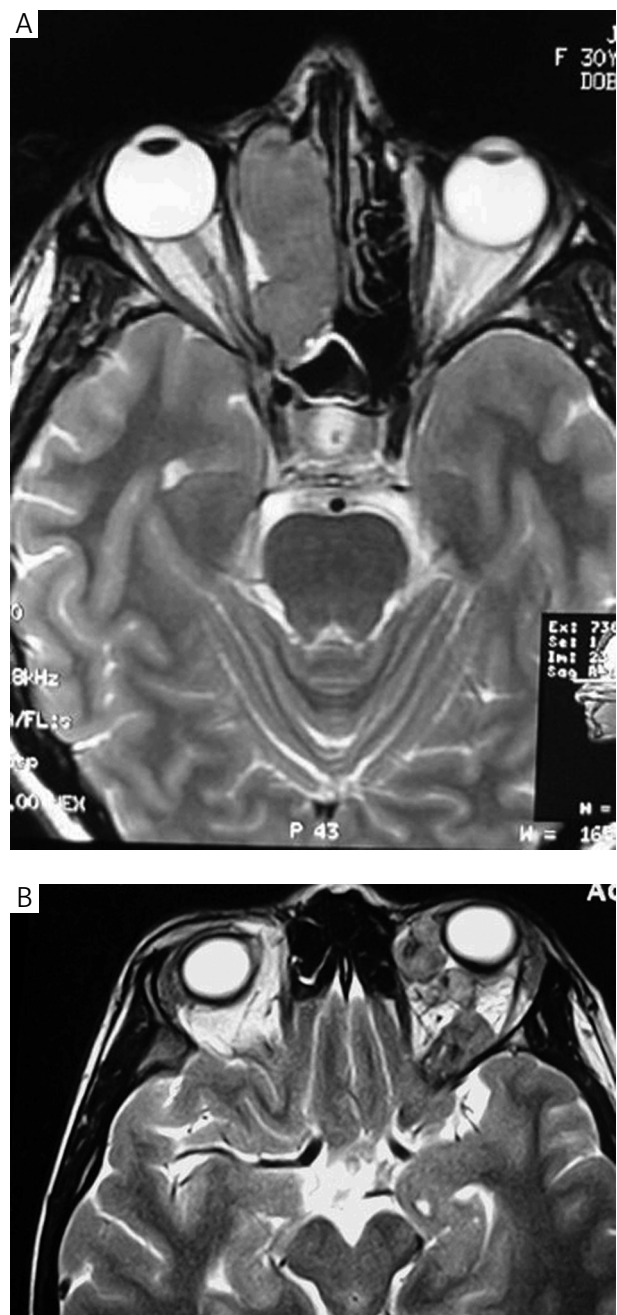
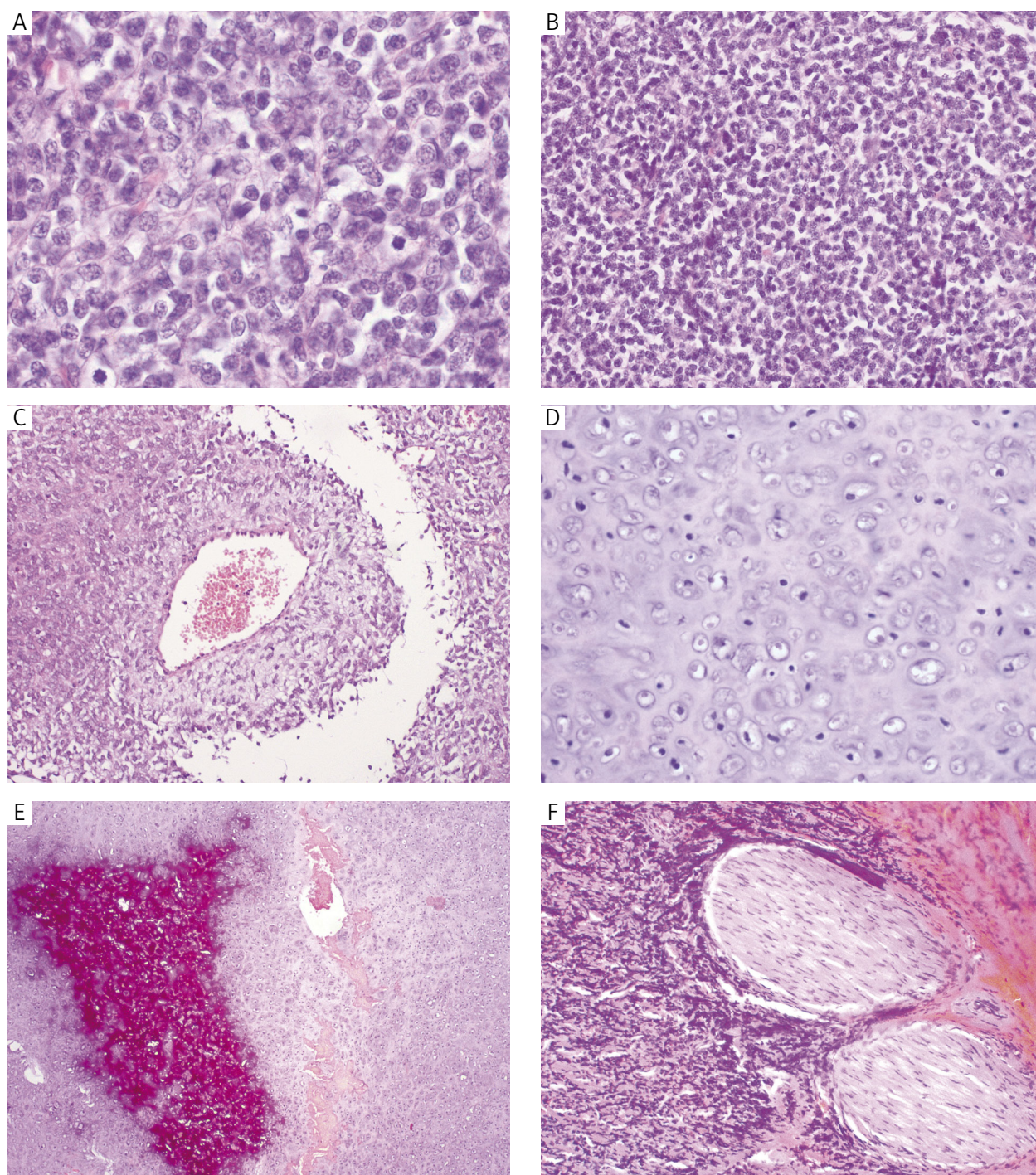


Fig. 1. Magnetic resonance imaging of MChS (A – case 1, B – case 2)



**Fig. 2.** Microscopic findings of MChS. A – Small, round to spindle-shaped cells – 40×. B – Sheets of small, round to spindle-shaped cells – 20×. C – Haemangiopericytoma-like pattern – 20×. D – Well differentiated cartilage – 40×. E – Calcifications – 20×. F – Invasion of surrounding tissues – 20× objective

### Treatment

Case 1: The tumor has been partially excised without surgical margins. Enucleation was recommended; however, the patient did not agree to the surgical treatment. The biopsy specimen was taken at that point. The patient had four courses of neoadjuvant chemotherapy (DDP 40 mg combined with VP16

140 mg). She has had no distant metastases for 10 months.

Case 2: The patient underwent a radical surgery with enucleation of the left eye. Proton beam therapy and a reconstructive surgery were considered. For 3.5 years after the initial diagnosis no distant metastases have been noted.

## Microscopic findings

The postoperative material of each case was fixed in formalin and embedded in paraffin. Five  $\mu\text{m}$  thick sections were cut from the paraffin blocks and stained with hematoxylin and eosin (HE). For immunohistochemistry, a DAKO autostainer automated staining system (DAKO Corporation, Carpinteria, CA, USA) was used with antibodies CD99, CD34, CD20, CD3 and LCA.

Both cases grossly appeared as a firm tan, multinodular tumor with hemorrhagic and necrotic foci as well as areas of calcification. The tumors were not well-delineated and the definite encapsulation was not present.

Microscopically, the tumors had a bimorphic pattern and were composed of cellular, undifferentiated, small mesenchymal cells and well-differentiated cartilage foci. The mesenchymal cells, small, round to spindle-shaped with hyperchromatic nuclei and scanty cytoplasm, occurred in sheets and surrounded vascular spaces in a haemangiopericytoma-like manner. Multiple calcifications within the central zone of cartilage were present.

Immunohistochemically, the positive membranous staining with CD99 was present. The reactions for CD34, CD3, CD20 and LCA antibodies were negative.

## Discussion

Mesenchymal chondrosarcoma (MChS), both skeletal and extraskeletal are high-grade aggressive tumors with a tendency for local recurrence and distant metastasis. Based on the published reports, approximately one third of all MChS are located extraskeletally, mostly in the lower extremities, meninges and the orbit [2]. The orbital location is rare and up-to-date only about 30 cases have been reported [7-9]. According to the review of the literature, most of the orbital tumors affect young patients, predominantly females (70-75%) [2]. Moreover, two congenital cases of MChS were described [9, 10]. The most frequent clinical symptoms are related to slowly enlarging soft-tissue mass and include progressive proptosis, gradually decreasing visual acuity, diplopia, ptosis and severe headache. As the tumor enlarges and becomes more advanced, the papillary edema is a typical finding in fundoscopy [7-9].

The imaging studies play an important role in the diagnostic evaluation of patients with the orbital MChS. On classical radiographs and computed tomography scans, a nonspecific soft-tissue mass is seen, often with mineralization areas of the cartilaginous matrix [11, 12]. Magnetic resonance imaging is more accurate in visualizing the infiltration of surrounding tissues by the tumor as well as determining areas of necrosis [13]. In addition, the prominent, diffuse and heterogeneous enhancement after intravenous administration of contrast is appreciated. The

high-flow vessels which may accompany the haemangiopericytoma-like areas may be identified [11].

The microscopic hallmark of MChS is a bimorphic pattern consisting of an admixture of highly cellular areas of undifferentiated mesenchymal cells with islands of well-differentiated cartilage [2, 14]. The immunohistochemical studies indicate the positive vimentin reaction for mesenchymal cells and S-100 for chondroid cells [15, 16]. Differential diagnosis of MChS may be difficult as the only available material is frequently a biopsy specimen. It should include a group of small round cell tumors: lymphoma, alveolar rhabdomyosarcoma, synovial sarcoma, Ewing sarcoma family of tumors, neuroblastoma and also an extraocular retinoblastoma, osteochondroma, meningioma and solitary fibrous tumor previously classified as haemangiopericytoma. Additional diagnostic tools include immunohistochemical, cytogenetic and molecular studies [17-19].

In a study of Naumann *et al.* [20], the cytogenetic analysis (Spectral Karyotype Analysis and Fluorescence in Situ Hybridization) of 3 MChS samples revealed the same chromosomal Robertsonian translocation der(13;21)(q10;q10). The authors emphasize that in 5 cases of previously analyzed MChS, the rearrangement has not been identified. Moreover, the molecular impact of the der(13;21)(q10;q10) still remains unclear. The remaining cytogenetic changes which were found in that study included loss of chromosome 8 and 20 material and gain of chromosome 12 material. Gatter *et al.* [21] describes the trisomy 8 as the sole cytogenetic abnormality in MChS. In other cytogenetic studies, a wide spectrum of genetic changes have been found. Szymańska *et al.* [22] reported multiple aberrations, i.e. t(4;9)(q23;q22), t(1;20)(q21;q13), add(10)(q?26), trisomy of chromosome 16 and ?del(19)(p13). Richkind *et al.* describe an apparently balanced t(4;19)(q35;q13.1) as the only MChS cytogenetic change [23]. Mandahl *et al.* revealed the complex hypertetraploid karyotype. An interesting finding of Sainati *et al.* was identification of t(11;22)(q24;q12) translocation. The authors suggest a genetic relationship between MChS, Ewing sarcoma and primitive peripheral neuroectodermal tumor (PNET). In accordance with the above hypothesis, an existence of the distinct tumor subgroup defined as "t(11;22)-small, round cell tumors" has been postulated [24].

The complexity and heterogeneity of MChS chromosomal aberrations, as well as its rarity, make it difficult to interpret the results obtained. The multicentric studies seem to be the only reliable way to clarify the cytogenetic and molecular changes of MChS. Recent molecular studies of MChS revealed a novel fusion of genes *HEY1* and *NCOA2* [25].

The "gold standard" of MChS treatment is a radical surgical excision of the tumor if clinically and anatomically feasible. Because MChS is a rare malig-

nancy there are no recommendations for radiotherapy with or without concomitant chemotherapy [4, 14]. The combined treatment should be advised in unresectable MChS cases and when the surgical margins are inadequate after surgery. There is a high frequency of local recurrences and distant metastases, most commonly to the lungs, regional lymph nodes and bones. The estimated survival rate is about 55% after 5 years and 27% after 10 years.

In conclusion, we present two cases of orbital MChS. The clinical presentation, imaging results and histopathological examination were typical of this rare entity. The presence of small, undifferentiated cells may be misinterpreted as Ewing sarcoma family of tumors, small cell osteosarcoma, lymphoma or rhabdomyosarcoma. Islands of cartilage and haemangiopericytoma-like pattern frequently facilitate the diagnosis of MChS.

## References

- Lichtenstein L. Unusual benign and malignant chondroid tumour of bone. *Cancer* 1959; 12: 1142-1157.
- Nakashima Y, Unni KK, Shives TC, et al. Mesenchymal chondrosarcoma of bone and soft tissue. A review of 111 cases. *Cancer* 1986; 57: 2444-2453.
- Blackwell JB. Mesenchymal chondrosarcoma arising in fibrous dysplasia of the femur. *J Clin Pathol* 1993; 46: 961-962.
- Goldenberg RR, Cohen P, Steinlauf P. Chondrosarcoma of the extraskelatal soft tissues. A report of seven cases and review of the literature. *J Bone Joint Surg Am* 1967; 49: 1487-1507.
- Chhem RK, Bui BT, Calderon-Villar H, Fontaine S. Case report: primary mesenchymal chondrosarcoma of the brain. *Clin Radiol* 1992; 45: 422-423.
- Rushing EJ, Armonda RA, Ansari Q, Mena H. Mesenchymal chondrosarcoma: a clinicopathologic and flow cytometric study of 13 cases presenting in the central nervous system. *Cancer* 1996; 77: 1884-1891.
- Odashiro AN, Leite LV, Oliveira RS, et al. Primary orbital mesenchymal chondrosarcoma: a case report and literature review. *Int Ophthalmol* 2009; 29: 173-177.
- Razak AR, Gurney L, Kirkham N, et al. Mesenchymal chondrosarcoma of the orbit: an unusual site for a rare tumour. *Eur J Cancer Care (Engl)* 2010; 19: 551-553.
- Tuncer S, Kebudi R, Peksayar G, et al. Congenital mesenchymal chondrosarcoma of the orbit: case report and review of the literature. *Ophthalmology* 2004; 111: 1016-1022.
- De Cecio R, Migliaccio I, Falletti J, et al. Congenital intracranial mesenchymal chondrosarcoma: case report and review of the literature in pediatric patients. *Pediatr Dev Pathol* 2008; 11: 309-313.
- Murphey MD, Walker EA, Wilson AJ, et al. From the archives of the AFIP: imaging of primary chondrosarcoma: radiologic-pathologic correlation. *Radiographics* 2003; 23: 1245-1278.
- Shinaver CN, Mafee MF, Choi KH. MRI of mesenchymal chondrosarcoma of the orbit: case report and review of the literature. *Neuroradiology* 1997; 39: 296-301.
- Hashimoto N, Ueda T, Joyama S, et al. Extraskelatal mesenchymal chondrosarcoma: an imaging review of ten new patients. *Skeletal Radiol* 2005; 34: 785-792.
- Huvos AG, Rosen G, Dabska M, Marcove RC. Mesenchymal chondrosarcoma. A clinicopathologic analysis of 35 patients with emphasis on treatment. *Cancer* 1983; 51: 1230-1237.
- Bagchi M, Husain N, Goel MM, et al. Extraskelatal mesenchymal chondrosarcoma of the orbit. *Cancer* 1993; 72: 2224-2226.
- Jacobs JL, Merriam JC, Chadburn A, et al. Mesenchymal chondrosarcoma of the orbit. Report of three new cases and review of the literature. *Cancer* 1994; 73: 399-405.
- Fanburg-Smith JC, Auerbach A, Marwaha JS, et al. Reappraisal of mesenchymal chondrosarcoma: novel morphologic observations of the hyaline cartilage and endochondral ossification and beta-catenin, Sox9, and osteocalcin immunostaining of 22 cases. *Hum Pathol* 2010; 41: 653-662.
- Fanburg-Smith JC, Auerbach A, Marwaha JS, et al. Immunoprofile of mesenchymal chondrosarcoma: aberrant desmin and EMA expression, retention of INI1, and negative estrogen receptor in 22 female-predominant central nervous system and musculoskeletal cases. *Ann Diagn Pathol* 2010; 14: 8-14.
- Hoang MP, Suarez PA, Donner LR, et al. Mesenchymal chondrosarcoma: a small cell neoplasm with polyphenotypic differentiation. *Int J Surg Pathol* 2000; 8: 291-301.
- Naumann S, Krallman PA, Unni KK, et al. Translocation der(13;21)(q10;q10) in skeletal and extraskelatal mesenchymal chondrosarcoma. *Mod Pathol* 2002; 15: 572-576.
- Gatter KM, Olson S, Lawce H, Rader AE. Trisomy 8 as the sole cytogenetic abnormality in a case of extraskelatal mesenchymal chondrosarcoma. *Cancer Genet Cytogenet* 2005; 159: 151-154.
- Szymanska J, Tarkkanen M, Wiklund T, et al. Cytogenetic study of extraskelatal mesenchymal chondrosarcoma. A case report. *Cancer Genet Cytogenet* 1996; 86: 170-173.
- Richkind KE, Romansky SG, Finklestein JZ. t(4;19)(q35;q13.1): a recurrent change in primitive mesenchymal tumors? *Cancer Genet Cytogenet* 1996; 87: 71-74.
- Sainati L, Scapinello A, Montaldi A, et al. A mesenchymal chondrosarcoma of a child with the reciprocal translocation (11;22)(q24;q12). *Cancer Genet Cytogenet* 1993; 71: 144-147.
- Wang L, Motoi T, Khanin R, et al. Identification of a novel, recurrent HEY1-NCO2 fusion in mesenchymal chondrosarcoma based on a genome-wide screen of exon level expression data. *Genes Chromosomes Cancer* 2012; 51: 127-139.

## Address for correspondence

Anna Szumera-Ciećkiewicz MD  
ul. Roentgena 5  
02-781 Warsaw, Poland  
e-mail: annacieckiewicz@coi.waw.pl